

## Case Series

# Results of minimally invasive quick definitive fixation of unstable bony pelvic disruption by combined retrosacral transiliac rods and anterior external fixator during a critical national period

Ahmed Refaat Khamis\*, Saad Abdelreheem Shoulah

Department of Orthopedic Surgery, Benha University Hospital, Benha, Egypt

**Received:** 27 March 2021

**Revised:** 14 April 2021

**Accepted:** 15 April 2021

**\*Correspondence:**

**Dr. Ahmed Refaat Khamis,**

E-mail: [ahmedkhamis73@yahoo.com](mailto:ahmedkhamis73@yahoo.com)

**Copyright:** © the author(s), publisher and licensee Medip Academy. This is an open-access article distributed under the terms of the Creative Commons Attribution Non-Commercial License, which permits unrestricted non-commercial use, distribution, and reproduction in any medium, provided the original work is properly cited.

### ABSTRACT

Unstable pelvic ring fractures are challenging injuries regarding their reduction and stabilization. The presented study evaluates the results of a minimally invasive and quick one-stage stabilization of sacral fractures combined with bilateral pubic rami fractures during a period of national limited resources and decreased general security aiming at reduction of the duration of hospital stay and overall costs. Sixteen patients with unilateral sacral fractures and bilateral pubic rami fractures without lumbosacral dissociation were fixed by two retrosacral threaded transiliac rods and an anterior external fixator. Results were assessed with Majeed score and Matta-Tornetta radiologic criteria for post-operative reduction. The follow up period averaged 23 months. There were 9 cases excellent, 4 cases good and 3 cases fair. The duration of surgery and the number of intra-operative X-ray images were recorded. The presented technique is simple, reproducible and quick for one-stage fixation of the unstable pelvic bony disruption. It reduces the operative time, radiation exposure, duration of hospital stays and cost of care during a critical national period with limited resources.

**Keywords:** Definitive fixation, Pelvic fractures, Pubic rami, Sacral fractures

### INTRODUCTION

Unstable fractures of the pelvic ring are challenging injuries regarding their reduction and fixation. Several techniques are present for fixation of the pelvic injury depending on the location and type of injury. Controversy exists about the easiness and biomechanical rigidity of each technique. Open reduction internal fixation is associated with blood loss and risk of neurovascular injury. Percutaneous fixation techniques need a deep experience, much radiation exposure and long operative time in some cases if reduction is difficult or the fixation method is not confirmed to be in the safe corridors. Disruption of the pelvic ring anteriorly or posteriorly is either a fracture or dislocation and the method of fixation

should depend on the nature of injury and the hemodynamic state of the patient at presentation.<sup>1,2</sup>

Sacral fractures are present in 45% of all pelvic fractures and 25% of them are associated with neurological injury. Young people are injured due to motor vehicle accidents or falls from a height while insufficiency sacral fractures occur in osteoporotic elderly patients after minor trauma. In most cases the anterior ring is fixed in supine position while the sacral fracture is fixed in prone position.<sup>3</sup>

The aim of the current study was to achieve definitive quick fixation of the pelvis in patients having unilateral sacral fracture with bilateral pubic rami fractures in the emergency theatre with the patient supine and with the

least number of intraoperative X-ray images. This target was planned to decrease the duration of hospital stay of patients and the overall costs of care during a critical national period with limited resources and general insecurity.

The results were assessed by Majeed functional pelvic score and Matta-Tornetta radiologic criteria. There were 9 excellent cases out of 16 cases. All cases united within 12 weeks. In 5 male cases overlap of the pubic rami with no functional disability was noted. Pin-tract infection with loosening of the external fixator and displacement of the sacral fracture caused limb shortening of about 2.2 centimeters was noted in the 3 cases of fair results.

The described technique is simple, fast, with minimal blood loss, short operative time and with acceptable complications rate in this severe form of pelvic disruption. It may restore the stability of the posterior pelvic ring by buttressing the sacral fracture on the axial and vertical planes both posteriorly and anteriorly. The technique is applicable in overcrowded trauma centers with limited financial resources.

### CASE SERIES

#### Presentation of cases

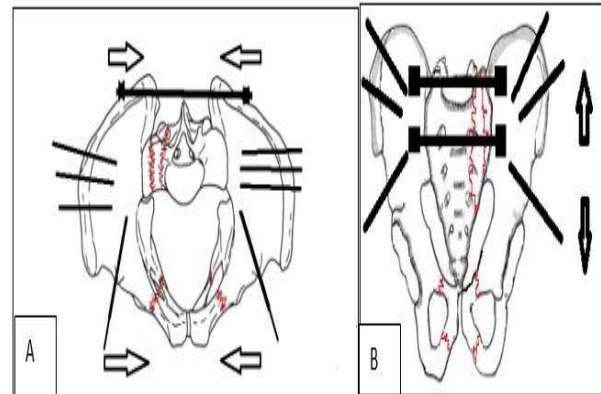
This therapeutic study was conducted between January 2011 and January 2015 on 16 patients during a critical national period with limited resources and general insecurity. There were 13 males and 3 females aged 21-48 years old. The pelvic fractures were 9 Tile type-B and 7 unstable type-C fractures. The mechanism of injury was motor vehicle accident in 13 cases and fall from a height in 3 cases. The type of fracture was bilateral pubic rami fractures and unilateral displaced fracture of the sacrum (Denis type-I in 9 cases and type-II in 7 cases).

All patients were hemodynamically stable at presentation. Initial assessment followed the ATLS protocol and pelvic anteroposterior, inlet and outlet views were taken to define the type of pelvic fracture. CT scan of the pelvis was obtained then the pelvic ring disruption was stabilized in the emergency theatre by anterior external fixator and posterior retro-sacral trans-iliac threaded rods in the same setting with the patient in supine position.

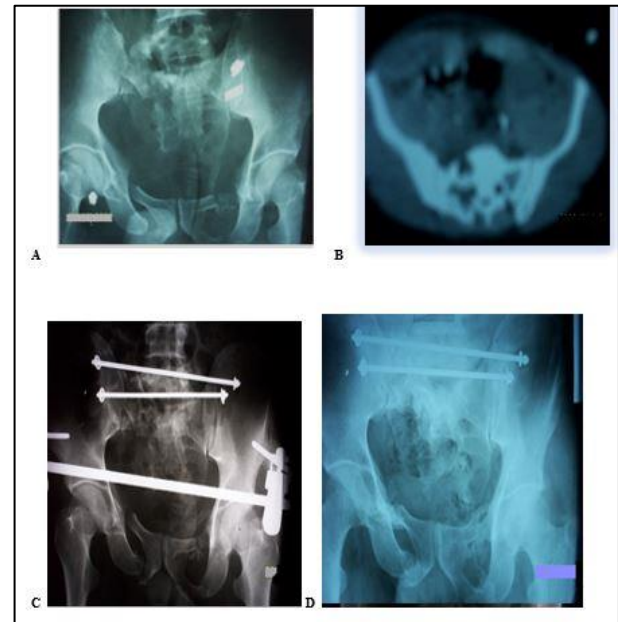
Patients with open pelvic fractures, bilateral or **Dennis-III** sacral fractures, hemodynamic instability or lumbopelvic dissociation were excluded from the study.

All cases were done in the emergency theatre with the patient supine and the pelvis is elevated from the table with a bolster under the lumbar spine to clear the area for insertion of the trans-iliac rods from the radiolucent table. The anterior external fixator was inserted first without X-rays to aid in reduction of the fractures by using the Schanz pins as joystick. In 8 cases the fixator was fixed in the iliac crest and in 8 obese patients we used a supracetabular

external fixator. Reduction of the posterior injury was done by axial traction vis a distal femoral pin and rotational displacement was corrected by using the external fixator pin to manipulate the fractured hemipelvis. Reduction was assessed on the image intensifier before insertion of the trans-iliac rods through two separate small incisions to minimize dissection through the posterior soft tissues starting on the side of the sacral fracture/posterior injury.

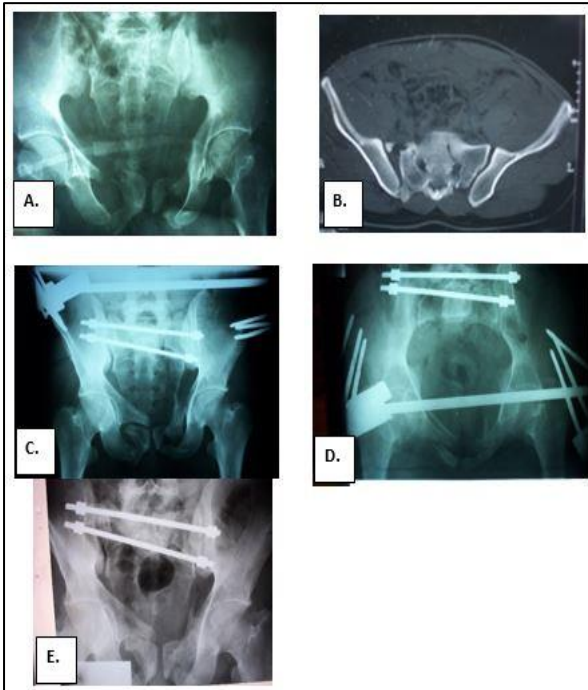


**Figure 1: Posterior sacral bars parallelogram and the anterior iliac or supra-acetabular external fixator buttressing the sacral fracture from behind and front together with pubic rami stabilization thus preventing medio-lateral (A) and cranio-caudal (B) displacement.**



**Figure 2: Denis-II sacral fracture with comminution (Case 15) (A) Pre-operative X-ray shows vertical displacement of right hemipelvis (B) CT-scan shows comminution (C) Postoperative X-ray after fixation shows residual displacement of 1.6 cm (D) Follow up X-ray after one year shows healing of rami fractures and sacral fracture.**

Sacral bars (Depuy-Synthes; 260 mm length - 6.0 mm diameter, a washer and two 6 mm blocking nuts) were inserted through a 6 mm drill holes in the posterior superior iliac spine (PSIS) 1.5 cm apart with the first bar inserted at the level of L5-S1 interspace as seen on the C-arm.



**Figure 3: (A, B) Non-displaced left Denis-II sacral fracture with right anterior sacroiliac disruption with anterior sacral avulsion and posterior small iliac crescent fracture. Post-operative X-rays (C: outlet, D: inlet) shows overlapped right superior ramus due to the internal rotation done to reduce the open right hemipelvis. (E) Follow up X-ray image after 6 months shows sound healing of the posterior lesion and residual displacement of right superior ramus (Case 2).**

We did not use K-wires for provisional stabilization of the posterior injury as described in the surgical technique of the manufacturing company as we relied on the external fixator for provisional stabilization of the pelvic ring. The bars were driven through the opposite PSIS with slow drilling till the tip approaches the skin on the opposite side where a small incision is made and the rest of the bar is driven out. The blocking nuts were applied on washers on both sides and tightened without much compression then the excess length of the bars is cut with a bolt cutter close to the blocking nuts (Figure 1).

Patients were allowed partial weight bearing on the non-injured side with a walking frame after 3 weeks and proceeded to full weight bearing after 8 weeks by which time the external fixator was removed in the outpatient clinic.

The duration of the operation, the number of intra-operative X-rays, and the duration of post-operative hospital stay were recorded for each patient.

All cases were followed clinically and radiologically for a period of 12-36 month and were evaluated for their functional ability by Majeed pelvic outcome score at the end of their follow up period. Radiological evaluation included the degree of vertical displacement of the hemipelvis and the degree of displacement of the pubic rami.

**(Table 1)** Among the 16 patients there were 13 males (81.2%) and 3 females (18.7%). The mechanism of injury was motor vehicle accident in 13 cases (81.2%) and fall from a height in 3 cases (18.7%). Age of the patients ranged between 21 and 48 years (average 34.5 year).

The posterior pelvic injuries were 9 Tile-B (56.2%) with sacral fractures of Denis type-I (56.2%); one of them had a bucket handle injury with contralateral sacroiliac anterior disruption, and 7 cases were Tile-C with sacral fracture of Denis type-II (43.7%). In all cases the anterior lesion was bilateral fracture of the superior and inferior pubic rami.

Seven cases (43.75%) had associated injuries. Two patients (12.5%) had ipsilateral fracture of the tibia and fibula shaft and two patients (12.5%) had ipsilateral femoral shaft fracture. These fractures were internally fixed with intramedullary nails in the same setting after pelvic fracture fixation. Three cases (18.75%) had preoperative L5-S1 neurologic deficit due to initial displacement of their sacral fractures that were of Denis type-II. This was improved during the follow up period.

The functional results after 12-36 months (average 24 month) follow up on Majeed pelvic outcome score were 9 cases (56.25%) excellent (score 78-80), 4 (25%) good (score 70-77) and 3 cases (18.75%) fair (score 60-69). Seven patients (43.7%) with excellent outcome had Denis-I sacral fractures and 2 patients (12.5%) had Denis-II sacral fractures. Ten patients (62.5%) completed follow up for 24 months, 4 patients (25%) completed 12 months, and 2 patients (12.5%) completed 36 months. An Arabic translation of Majeed score was prepared and given to each patient at the final follow up to report their personal functional score related to their daily activities.

The final radiological evaluation showed vertical displacement of 0.5-1.6 centimeters of the fractured hemipelvis in 4 patients (25%) whose functional outcome score was good. Three cases (18.75%) whose functional outcome score was fair showed vertical displacement and limb shortening of about 2.2 cm. The three male cases (18.75%) with fair outcome had pubic rami fracture overlap of 2.2- 2.4 cm that healed without urological complications. This overlap was not corrected intraoperatively as it was necessary to achieve reduction of the posterior injury by internal rotation of the fractured hemipelvis (Figures 2,3).

We had no post-operative iatrogenic neurologic complications reported from compression of the sacral nerve roots after reduction of the sacral fractures and no urologic complications after reduction of the pubic rami fractures. The 3 cases (18.75%) with fair outcome had pin tract infection that caused loosening of the fixators after 2

weeks and required removal of the fixators and debridement of the pin tracts under antibiotic coverage. The 4 patients (25%) with good outcome had mild pain with activity at the site of insertion of the sacral rods. One of them (6.25%) whose BMI was 18.5 had more pain that necessitates removal of the sacral bars after 6 months.

**Table 1: Results of the presented cases including their outcome score, radiological results and complications.**

Case	Age, Sex	Injury mech	Sacral fracture; Dennis	Op time min	Intra-op X-rays	Post-op stay	Majeed score	Ant disp	Post disp	Complications	Asso inj	Follow Up
1	40 M	MVA	1	40	3	6	E	-	-	-	-	24
2	42 F	MVA	2	55	7	8	E	2.5	-	-	L5-S1	24
3	24 M	MVA	2	60	8	8	G	0.3	1.2	PAI N	L5-S1	24
4	32 M	MVA	1	40	4	7	E	-	-	-	-	12
5	27 M	MVA	1	43	5	7	E	-	-	-	-	24
6	34 M	MVA	1	43	4	7	E	-	-	-	-	36
7	29 M	MVA	1	45	4	8	E	0.6	-	-	-	24
8	27 F	FFH	1	49	5	8	G	-	0.5	PAI N	-	24
9	21 M	MVA	2	65	8	10	E	0.2	-	-	FEM UR	36
10	23 M	MVA	1	45	4	7	E	-	-	-	-	24
11	37 F	MVA	1	50	5	8	G	-	1.5	PAI N	-	12
12	33 M	MVA	2	75	9	10	F	0.5	2	LOO SE	TIBI A	24
13	48 M	MVA	1	43	3	8	E	-	-	-	-	24
14	45 M	MVA	2	69	9	10	F	2.2	1.5	LOO SE	FEM UR	12
15	31 F	FFH	2	65	9	8	G	-	1.6	PAI N	L5-S1	12
16	35 M	FFH	2	73	9	10	F	2.4	2.5	LOO SE	TIBI A	24



The operative time for reduction and fixation was 40-75 minutes (average 57.5 min). The longer operative time was reported in cases with displaced sacral Denis-II fractures. The amount of intra-operative blood loss was negligible in all cases as all fixations were done through minimally invasive incisions. The number of C-arm images taken for pelvic fixation was 3-5 images in 9 cases (62.5%) with Denis type-I sacral fracture and 7-9 images in 7 cases

(37.5%) with Denis type-II sacral fracture in whom reduction of the fractures needed more time.

The duration of post-operative hospital stay was 6-8 days in 12 patients (75%) and 10 days in 4 patients (25%) who had associated long bones fractures.



## DISCUSSION

With unstable sacral fractures in the acute post-traumatic setting, the goal is to achieve a non-invasive pelvic volume reduction and fracture stabilization to minimize additional blood loss. Nondisplaced sacral fractures can be fixed through posterior percutaneous approaches. The role of external fixation alone for treatment of pelvic fractures is now limited to the emergency management of hemodynamic instability.<sup>1,2</sup>

Acute surgical decompression of sacral nerve roots is associated with risk of bleeding, wound complications and CSF leak however, surgery is considered if there is a chance to restore even a unilateral distal root function for voluntary bowel and bladder control. Neurological improvement of up to 80% is frequent, regardless of the type of operative or conservative management. With satisfactory skeletal stabilization but persistent foraminal or spinal canal compromise, a focal decompression may be performed within two weeks after injury, through a midline approach X-ray-guided focal laminectomy. Spinopelvic dissociation associated with neurologic lesions hardly ever recover completely, with residual lower-limb neurologic deficits, urinary problems and sexual dysfunction.<sup>1-3</sup> Three cases in our study had preoperative L5-S1 neurologic deficit that showed improvement after reduction and fixation of their Denis-II sacral fractures.

Vertically unstable sacral fractures are often difficult to fix rigidly with no consensus on an optimal fixation technique. Variable fixation methods exist through long operations, much radiation exposure, risk of injuring the sacral nerve roots and posterior soft tissues infection with ORIF especially with Morel-Lavallée lesion. **Early definitive fixation of pelvic ring fractures facilitates reduction while delay more than 5 days after injury may result in poor closed reduction accuracy.**<sup>2,4</sup>

Fixation of the anterior pelvic injury increases overall stability and reduces the risk of posterior implant failure. It is easier and faster to place the fixator pins in the **iliac crest - even without fluoroscopy - than** in the supraacetabular region. Anterior external fixator alone does not restore posterior pelvic stability especially with sacroiliac (SI) dislocation. Caution is required to avoid perforation of the thin iliac plate and to avoid over-compression of the sacral nerve roots on attempted reduction of the pelvic ring in cases with comminuted sacral fractures.<sup>5</sup>

The sacrum is the key stone in the posterior pelvic tension band-roman arch construct being suspended from the posterior SI ligaments and fixed to the ilium by the interosseous and anterior SI ligaments. Normally the sacrum moves 2-4 mm in the frontal plane and in the transverse plane around an oblique axis of rotation at the SI joint in nutation and counternutation movements transmitting loads from the spine to the pelvis. The goal of

surgical fixation is to reconstruct the posterior tension band construct of the pelvis to allow early weight-bearing particularly for multiple injured patients. The lumbosacral pivot point is the axis of rotation between L5 vertebral body and the sacrum located at the intersection of the middle osteo-ligamentous column and the L5-S1 disc. Sacral fixation constructs should be dorsal to this point and should extend anteriorly according to Galveston technique to resist stresses and to provide medio-lateral rotational stability.<sup>6,7</sup> In the current study we applied this principle by the posterior rods to fix the sacrum on the fractured side to the intact contralateral hemipelvis and the anterior fixator for indirect anterior buttressing of the sacral fracture and stabilization of the rami fractures.

Sacral bars (retro-sacral trans-iliac threaded rods), trans-iliac internal fixator (TIFI), iliosacral screws, posterior tension band plates, triangular lumbo-pelvic osteosynthesis, and ilio-sacral-iliac rods are available options for sacral fractures fixation with numerous advantages and disadvantages. The fixation method should depend on whether the injury is a fracture or a dislocation because pelvic bones are rich in blood supply and heal faster than the dislocations which necessitate a more rigid fixation method.<sup>2,3,6</sup>

The mean biomechanical strength of a single iliosacral screw is 819 N and 1066 N for transiliac bars. After 400 cycles of weight bearing, iliosacral screws fail at 50 N load in vertical displacement, posterior tension band plate fail at 100 N load in rotational displacement, while sacral plate combined with iliosacral screws can resist 100 N load but rotational failure still occur. Trans-sacral bar in S1 connected with a transiliac bar in the PSIS by a link bar on the outer table of ilium could resist 500 N loads. The ilio-sacral-iliac fixation reduces segmental flexion-extension motions with loading more than S1-S2 iliosacral screws. Joint disruption needs a more rigid fixation. In cases of symphyseal disruption with Denis-II sacral fracture, symphyseal plates and sacral rods can restore 65-71% of the intact pelvis strength, while 46% of the strength can be restored by sacral rods and anterior Hoffmann frame.<sup>7,8</sup> The current study construct allowed for **restoration** the posterior tension band of the pelvic ring. The external fixator allowed for fractures reduction and anterior support of the sacral fracture without prevention of the sacral nutation motion by preventing medio-lateral displacement in the axial plane. This construct created a "parallelogram" that resists translation in the anteroposterior, mediolateral and craniocaudal planes.

Most fractures of the pubic rami do not require stabilization. Internal fixation should be reserved for symphyseal disruption and a minority of pubic rami fractures. Although its use for definitive fixation has been recently declined, external fixation remains a favorable option in certain situations. The subcutaneous internal fixator (INFIX) is a good option in obese patients who poorly tolerate external fixation. It uses supra-acetabular pedicular screws or iliac screws (cross-over internal

fixator) connected with a curved suprapubic rod. The INFIX is relatively minimally invasive and time-saving technique especially in patients with pelvic organ injuries however, the evidence for its use is limited, its cost is high, it requires a second operation for removal with specific instruments and a higher functional outcome could be obtained with plating. It is also associated with injury to the lateral femoral cutaneous nerve (LFCN) in 30% of patients and femoral nerve palsies due to impingement of the bar on psoas sheath causing delayed femoral palsy due to psoas engorgement with blood in the standing position.<sup>9-13</sup> In our study, we used Hoffman external fixator for its availability, low cost, easiness of application, proved rigidity and its easy removal as an outpatient procedure. We had 3 cases (18.7%) of pin tract infection with iliac fixators but no cases of LFCN injury with supra-acetabular fixator. In those 3 cases the fixator became loose and secondary sacral fracture displacement caused about 2.2 cm of limb shortening made their outcome fair. Our final functional results were 43.75% excellent, 37.5% good and 18.75% fair on Majeed score. (Table 1)

Reduction and stabilization of the posterior injury is crucial regardless of the anterior injury fixation to restore pelvic ring stability. Open reduction and fixation of dorsal injuries has a high rate of soft tissue complications. Minimally invasive approaches reduce soft tissue trauma but carry the risk of iatrogenic neurovascular injury through the reduced surgical exposure.<sup>14,15</sup> Vallier et al, reviewed 333 unilateral sacral fractures (92% LC, 63% zone-1) managed in 16 trauma centers. They found that many similar fractures were treated operatively and conservatively by different surgeons. Operative patients (54%) were zone-2 fractures with posterior cortical displacement. Rotational displacements were not different between operative and non-operative patients. These findings support the need to develop consistent indications for surgical treatment of type-I and II sacral fractures.<sup>16</sup>

Triangular osteosynthesis (TOS) for transforaminal sacral fractures is a technically demanding rigid fixation especially in cases of spinopelvic dissociation. Pain from prominence of the pedicular screws heads, L5-S1 facet joint distraction, iatrogenic L5 root injury from manipulation, wound problems, residual displacement and loosening of fixation are reported complications.<sup>16,17</sup> This technique should be reserved as a salvage procedure for unstable sacral fractures if other fixation methods are not applicable.<sup>18</sup>

Iliosacral screws (ISS) are commonly used to fix posterior injuries (SI joint dislocations, sacral fractures, type-III crescent fractures and combined injuries). A single ISS may not be a sufficiently stable fixation. Hardware failure, misplacement of screws, nerve injury and poor reduction were reported. Even experienced surgeons can have a mal-positioned screw and neurovascular injuries, thus ISS fixation must be performed under the best fluoroscopy control, but in the ER setting, this could be laborious and time consuming. To overcome these biomechanical

limitations, dual ISS fixation in S1 and S2 was developed. Fixation across the contralateral intact SI joint resulted in no differences in pain and function after one year when compared with standard ISS fixation across the injured side.

Sacral dysmorphism was reported in 47% of patients in one study making percutaneous placement of ISS in S1 difficult in many cases. Preoperative planning and a high quality tri-planar intra-operative images are mandatory to place trans-sacral implants through the variable dimensions of the safe corridors in S1 and S2. A screw placement in S2 is safe however, it is difficult to remove a mal-positioned or broken screw and to revise the fixation in cases of sacral non-union. Methods to accurately identify a specific entry point and aiming point for ideal screw position in each sacrum (perpendicular to SI joint) to avoid screw misplacement, reduce the operating time and radiation exposure have not been described yet.<sup>19-26</sup> In our study, the sacral bars were placed behind the sacrum away from the sacral nerve roots in a short operative time even in cases of sacral dysmorphism with minimal radiation exposure and the ability to do the technique in the emergency setting.

Retro-sacral trans-iliac bars for zone-II sacral fractures did not fall out of favor yet. Modification of the technique by fixation of the bar to two adjustable plates on the PSIS in prone position showed comparable results with TOS and two ISS fixation techniques. The trans-iliac internal fixator (TIFI) is another modification (2 long iliac pedicular screws in PSIS connected to a retro-sacral rod) with no significant differences in 3-D deformation when compared to ISS and anterior SI plating. It gave 66% excellent results in unstable sacral fractures fixation however, the TIFI is more posterior in the iliac bones than the trans-iliac bars with the side effect of screw head painful protrusion. Being inserted in the prone position, the TIFI is not suitable in the acute management of hemodynamically unstable or polytraumatized patients.<sup>27,28</sup> The sacral bars used in our study were not protruding on the soft tissues but 4 cases reported some pain with activity at the bar insertion site, one of them who was thin needed removal of the rods after union of the fractures.

Percutaneous fixation after closed reduction by traction in supine position allows better reduction of the fractures than open reduction and fixation in prone position. Percutaneous or open plate fixation of unstable sacral fractures in prone position before fixation of the anterior lesion in supine position offers 28% - 85% excellent results among studies. It is not recommended in hemodynamically unstable patients, major SI joint fracture dislocation, posterior Morel-Lavallee lesion, and in nondisplaced sacral fractures.<sup>29</sup> The anterior and posterior fixation in our study were done in supine position to facilitate reduction and fixation of both fractures of the pelvic ring.

No statistically significant difference in residual displacement and Majeed score was reported between ISS

and percutaneous plating of unstable sacral fractures. Anterior plating of unstable sacral fractures through pararectal approach can achieve 91.6% excellent to good result on Majeed score however, it is a long operation with more blood loss.<sup>30-33</sup> In the current study, the blood loss amount is negligible and the operative time is short.

Our results (Table 1) were comparable to those of Chiu et al, and Harma et al.<sup>3,35</sup> Chiu et al, used sacral rods and anterior AO external fixator in 42 type-C pelvic injuries. Their results were 64.6% satisfactory, 35.4% unsatisfactory, 26% persistent posterior pain, 24% irreversible neurologic deficit, 3% posterior wound infection, 4.6% pin tract infection, and 6% irreversible urologic deficit after average 85 months follow up. They concluded that combined sacral rods and anterior external fixation for type-C pelvic fractures without iliac fracture, yield good radiologic results and the functional results were correlated mainly with avoidance of complications and not necessarily with the radiologic results. We had no persistent neurologic deficit in our study possibly due to the very early reduction and fixation of the pelvic injury without changing the position of the patient from supine to prone. Harma et al used TIFI and anterior lesion external fixator or plating in 14 zone-II sacral fractures. They reported 71% excellent results, 14% good and 14% moderate. In our study we had 25% good and 18.75% fair results but less excellent outcome (56.25%). This difference could be because their anterior ring fixation method was by plating in some cases.

Residual vertical displacement and site of the posterior lesion are correlated with the functional outcome only to some extent and other factors could be implicated. Mental and emotional deficits are not covered in the pelvic fracture outcome scores making assessment of the functional outcome and health-related quality of life (HRQOL) suboptimal and difficult for surgeons. The majority of patients do not return to the same preinjury activities and late morbidity is correlated with the severity of fracture, associated injuries, fracture-related complications, male patients, methods of treatment, and delayed weight bearing. With residual displacement less than 1 cm for SI/symphysis disruption, the injury mechanism and associated injuries have no impact on the functional outcome or HRQOL. On Majeed score, poor results were seen in males, associated injuries (urogenital, neurological and acetabular/sacral fractures) and soft tissue complications. No association was found with age, fracture pattern, treatment modality and timing of surgery.<sup>36-39</sup> Even the functional results differ with the score used in one study on 26 complex Tile-C fractures after internal fixation where 50% were excellent on Majeed score while 80% were excellent on Hannover score. The fracture type was statistically insignificant with acquired sexual dysfunction, but significant with the chronic pain.<sup>40</sup>

In our study an Arabic translation of Majeed score was filled by the patients at final follow up to evaluate the

functional outcome of treatment from the patient perspective. The type of fracture was not related to the functional outcome but residual posterior displacement did. Two cases with excellent outcome had a Denis-II sacral fracture that was nondisplaced and 2 cases with good outcome had Denis-I sacral fracture with 0.5-1.5 cm residual displacement while one case with Denis-II sacral fracture and 1.6 cm displacement had a good outcome. All the seven patients with associated injuries in our study had a Denis-II sacral fractures. Two of them had excellent functional result with no sacral displacement, two had good results with 1.2-1.6 cm residual sacral displacement and the 3 cases with fair result had more (1.5-2.5 cm) posterior displacement. The anterior lesion residual displacement was not related to outcome as 3 cases with excellent outcome had rami residual displacement of 0.2 to 2.5 cm, and one case with good outcome had 0.3 cm rami displacement.

## CONCLUSION

The current study showed that fixation with sacral bars combined with an anterior external fixator is still an easy, safe and useful method for treating bony pelvic ring disruption of combined sacral fracture and bilateral pubic rami fractures with acceptable functional outcome and complications rate. The technique offers a quick minimally invasive biologic stabilization of the pelvic ring in supine position. This advantage is useful in hospitals with limited resources and during war or critical national times. A more rigid fixation method is required in cases of disruption of the posterior or anterior joints of the pelvic ring.

*Funding: No funding sources*

*Conflict of interest: None declared*

*Ethical approval: Not required*

## REFERENCES

1. Mehta S, Auerbach JD, Born CT, Chin KR. Sacral fractures. *J Am Acad Orthop Surg*. 2006;14(12):656-65.
2. Santolini E, Kanakaris N, Giannoudis P. Sacral fractures: issues, challenges, solutions. *EFORT Open Rev*. 2020;5(5):299-311.
3. Sasso RC, Vaccaro AR, Chapman JR, Best NM, Zdeblick TA, Harris MB. Sacral fractures. *Instr Course Lect*. 2009;58:645-55.
4. Routt ML Jr, Nork SE, Mills WJ. Percutaneous fixation of pelvic ring disruptions. *Clin Orthop Relat Res*. 2000;375:15-29.
5. Encinas-Ullán CA, Martínez-Diez JM, Rodríguez-Merchán EC. The use of external fixation in the emergency department: applications, common errors, complications and their treatment. *EFORT Open Rev*. 2020;5(4):204-214.
6. McCord DH, Cunningham BW, Shono Y, Myers JJ, McAfee PC. Biomechanical analysis of lumbosacral fixation. *Spine (Phila Pa 1976)*. 1992;17(8):S235-43.

7. Berber O, Amis AA, Day AC. Biomechanical testing of a concept of posterior pelvic reconstruction in rotationally and vertically unstable fractures. *J Bone Joint Surg Br*. 2011;93(2):237-44.
8. Cunningham BW, Sponseller PD, Murgatroyd AA, Kikkawa J, Tortolani PJ. A comprehensive biomechanical analysis of sacral alar iliac fixation: an in vitro human cadaveric model. *J Neurosurg Spine*. 2019;30(3):367-75.
9. Wright RD Jr. Indications for Open Reduction Internal Fixation of Anterior Pelvic Ring Disruptions. *J Orthop Trauma*. 2018;32(6):S18-23.
10. Wojahn RD, Gardner MJ. Fixation of Anterior Pelvic Ring Injuries. *J Am Acad Orthop Surg*. 2019;27(18):667-76.
11. Kuttner M, Klaiber A, Lorenz T, Füchtmeier B, Neugebauer R. The pelvic subcutaneous cross-over internal fixator. *Unfallchirurg*. 2009;112(7):661-9.
12. Steer R, Balendra G, Matthews J, Wullschlegler M, Reidy J. The use of anterior subcutaneous internal fixation (INFIX) for treatment of pelvic ring injuries in major trauma patients, complications and outcomes. *SICOT J*. 2019;5:22.
13. Dahill M, McArthur J, Roberts GL, Acharya MR, Ward AJ, Chesser TJS. The use of an anterior pelvic internal fixator to treat disruptions of the anterior pelvic ring a report of technique, indications and complications. *Bone Joint J*. 2017;99-B(9):1232-6.
14. Mosheiff R, Liebergal M, Fridman A, Sagiv S, Segal D. Immediate posterior stabilization of pelvic fractures using threaded compression rods. *Harefuah*. 1996;131(7-8):217-21.
15. Dienstknecht T, Berner A, Lenich A, Zellner J, Mueller M, Nerlich M, et al. Biomechanical analysis of a transiliac internal fixator. *Int Orthop*. 2011;35(12):1863-8.
16. Vallier HA, Lowe JA, Agel J, Mullis BH, Jones CB, Teague D, et al. Surgery for Unilateral Sacral Fractures: Are the Indications Clear? *J Orthop Trauma*. 2019;33(12):619-25.
17. Schildhauer TA, Josten Ch, Muhr G. Triangular osteosynthesis of vertically unstable sacrum fractures: a new concept allowing early weight-bearing. *J Orthop Trauma*. 2006;20(1):S44-51.
18. Jones CB, Sietsema DL, Hoffmann MF. Can lumbopelvic fixation salvage unstable complex sacral fractures? *Clin Orthop Relat Res*. 2012;470(8):2132-41.
19. Alvis-Miranda HR, Farid-Escorcía H, Alcalá-Cerra G, Castellar-Leones SM, Moscote-Salazar LR. Sacroiliac screw fixation: a mini review of surgical technique. *J Craniovertebr Junction Spine*. 2014;5(3):110-3.
20. Zhao Y, Li J, Wang D, Liu Y, Tan J, Zhang S. Comparison of stability of two kinds of sacro-iliac screws in the fixation of bilateral sacral fractures in a finite element model. *Injury*. 2012;43(4):490-4.
21. Heydemann J, Hartline B, Gibson ME, Ambrose CG, Munz JW, Galpin M, et al. Do Trans-sacral-transiliac Screws Across Uninjured Sacroiliac Joints Affect Pain and Functional Outcomes in Trauma Patients? *Clin Orthop Relat Res*. 2016;474(6):1417-21.
22. Wagner D, Kamer L, Sawaguchi T, Noser H, Uesugi M, Baranowski A, et al. Space available for trans-sacral implants to treat fractures of the pelvis assessed by virtual implant positioning. *Arch Orthop Trauma Surg*. 2019;139(10):1385-91.
23. Osterhoff G, Noser J, Sprengel K, Simmen HP, Werner CML. Rate of intraoperative problems during sacroiliac screw removal: expect the unexpected. *BMC Surg*. 2019;19(1):39.
24. Routt ML Jr, Simonian PT, Mills WJ. Iliosacral screw fixation: early complications of the percutaneous technique. *J Orthop Trauma*. 1997;11(8):584-9.
25. Ecker TM, Jost J, Cullmann JL, Zech WD, Djonov V, Keel MJB, et al. Percutaneous screw fixation of the iliosacral joint: A case-based preoperative planning approach reduces operating time and radiation exposure. *Injury*. 2017;48(8):1825-30.
26. Zhang R, Yin Y, Li S, Guo J, Hou Z, Zhang Y. Sacroiliac screw versus a minimally invasive adjustable plate for Zone II sacral fractures: a retrospective study. *Injury*. 2019;50(3):690-696.
27. Fathy Saoud AM, Sallam AM. Minimal Access Fixation of Longitudinal Sacral Fractures: The Posterior Internal Fixator with a Minimum of Three Years of Follow-Up. *World Neurosurg*. 2018;119:511-6.
28. Salásek M, Pavelka T. Minimally invasive fixation of the pelvic ring with a transiliacal internal fixator. *Acta Chir Orthop Traumatol Cech*. 2012;79(4):335-40.
29. Lindsay A, Tornetta P 3rd, Diwan A, Templeman D. Is Closed Reduction and Percutaneous Fixation of Unstable Posterior Ring Injuries as Accurate as Open Reduction and Internal Fixation? *J Orthop Trauma*. 2016;30(1):29-33.
30. Chen HW, Liu GD, Ou S, Zhao GS, Pan J. Treatment of unstable sacral fractures with percutaneous reconstruction plate internal fixation. *Acta Cir Bras*. 2012;27(5):338-42.
31. Khaleel VM, Pushpasekaran N, Prabhu N, Pandiyan A, Koshy GM. Posterior tension band plate osteosynthesis for unstable sacral fractures: A preliminary study. *J Clin Orthop Trauma*. 2019;10(1):S106-11.
32. Acklin YP, Marco G, Sommer C. Double locking plate fixation of sacral fractures in unstable pelvic ring C-type injuries. *Oper Orthop Traumatol*. 2015;27(1):74-9.
33. Huang H, Xing W, Zeng C, Huang W. Pararectus approach combined with three-dimensional printing for anterior plate fixation of sacral fractures. *Injury*. 2020;S0020-1383.
34. Chiu FY, Chuang TY, Lo WH. Treatment of unstable pelvic fractures: use of a transiliac sacral rod for posterior lesions and an external fixator for anterior lesions. *J Trauma*. 2004;57(1):141-4.



35. Harma A, Inan M. Surgical management of transforaminal sacral fractures. *Int Orthop*. 2005;29(5):333-7.
36. Inokuchi K, Kamimura N, Yamakawa K, Saiki K, Hirabayashi S, Tsuzuki N. Functional outcome of patients with unstable pelvic fractures. *JBJS. Orthopaedic Proceedings*. 2018;85.
37. Lefaivre KA, Slobogean GP, Ngai JT, Broekhuysen HM, O'Brien PJ. What outcomes are important for patients after pelvic trauma? Subjective responses and psychometric analysis of three published pelvic-specific outcome instruments. *J Orthop Trauma*. 2014;28(1):23-7.
38. Rickman M, Link BC, Solomon LB. Patient Weight-bearing after Pelvic Fracture Surgery-A Systematic Review of the Literature: What is the Modern Evidence Base? *Strategies Trauma Limb Reconstr*. 2019 ;14(1):45-52.
39. Verma V, Sen RK, Tripathy SK, Aggarwal S, Sharma S. Factors affecting quality of life after pelvic fracture. *J Clin Orthop Trauma*. 2020;11(6):1016-24.
40. Ghosh S, Aggarwal S, Kumar P, Kumar V. Functional outcomes in pelvic fractures and the factors affecting them- A short term, prospective observational study at a tertiary care hospital. *J Clin Orthop Trauma*. 2019;10(5):896-9.

**Cite this article as:** Khamis AR, Shoulah SA. Results of minimally invasive quick definitive fixation of unstable bony pelvic disruption by combined retrosacral transiliac rods and anterior external fixator during a critical national period. *Int J Res Orthop* 2021;7:xxx-xx.